

# Intracardiac Visualization of Transcatheter Mitral Valve Repair in an In Vitro Passive Beating Heart

Guido Gelpi, MD; Claudia Romagnoni, MD; Riccardo Vismara, PhD; Andrea Mangini, MD; Monica Contino, MD; Beniamino Fiore Gianfranco, PhD; Carlo Antona, MD

Transcatheter mitral valve repair has emerged as a feasible and safe alternative in patients with contraindications for surgery or high operative risk.<sup>1</sup> Cardiac imaging plays a central role in selecting patients, guiding the procedure, and evaluating the durability of the repair at follow-up.

Real-time 3-dimensional transesophageal echocardiography is a key point to visualize and optimize transcatheter mitral valve repair for a good result. However, the chance to clarify, step by step, mitral repair with intracardiac visualization expands the knowledge of the procedure itself.

We video-recorded atrial and ventricular views of MitraClip (Abbot Vascular, USA) implant procedures in a platform with swine passive beating hearts.<sup>2,3</sup> The procedures were performed in a physiological mitral valve and in a type II mitral regurgitation model.

Movie I in the online-only Data Supplement shows intracardiac visualization of the implant in physiological conditions highlighting the different steps of clip positioning and the interaction with the surrounding heart structures.

Movie II in the online-only Data Supplement shows intracardiac visualization of the implant for treatment of P2 mitral flail; this video outlines the grasping of the flail and the resulting double-orifice mitral valve.

Echocardiographic images and cardiac output recorded during the procedure (representative snapshots are reported in the Figure) allowed us to assess the anatomic and functional result of the procedure.

The possibility to directly view the mitral valve repair procedure gives the clinician a novel awareness of each step of the implantation, and it provides a direct feedback on the interaction of the device with the surrounding structures.

These direct views, together with the possibility to simultaneously record standard imaging techniques and to evaluate the effects of the procedure on the hemodynamic parameters, make the in vitro platform a promising tool for educational and training purposes.

## Acknowledgments

We sincerely thank Fabio Simone for his kind help and the assistance in the performance of the procedures.

## Disclosures

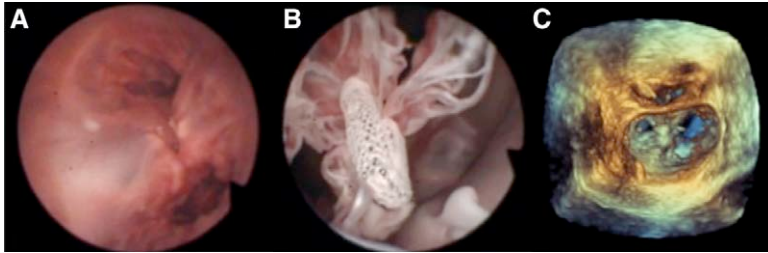
None.

## References

1. Nickenig G, Estevez-Loureiro R, Franzen O, Tamburino C, Vanderheyden M, Lüscher TF, Moat N, Price S, Dall'Ara G, Winter R, Corti R, Grasso C, Snow TM, Jeger R, Blankenberg S, Settergren M, Tiroch K, Balzer J, Petronio AS, Büttner HJ, Etori F, Sievert H, Fiorino MG, Claeys M, Ussia GP, Baumgartner H, Scandura S, Alamgir F, Keshavarzi F, Colombo A, Maisano F, Ebelt H, Aruta P, Lubos E, Plicht B, Schueler R, Pighi M, Di Mario C; Transcatheter Valve Treatment Sentinel Registry Investigators of the EURObservational Research Programme of the European Society of Cardiology. Percutaneous mitral valve edge-to-edge repair: in-hospital results and 1-year follow-up of 628 patients of the 2011-2012 Pilot European Sentinel Registry. *J Am Coll Cardiol*. 2014;64:875-884. doi: 10.1016/j.jacc.2014.06.1166.
2. Leopaldi AM, Vismara R, Lemma M, Valerio L, Cervo M, Mangini A, Contino M, Redaelli A, Antona C, Fiore GB. *In vitro* hemodynamics and valve imaging in passive beating hearts. *J Biomech*. 2012;45:1133-1139. doi: 10.1016/j.jbiomech.2012.02.007.
3. Leopaldi AM, Vismara R, Gelpi G, Romagnoni C, Fiore GB, Redaelli A, Lemma M, Antona C. Intracardiac visualization of transcatheter aortic valve and valve-in-valve implantation in an *in vitro* passive beating heart. *JACC Cardiovasc Interv*. 2013;6:92-93. doi: 10.1016/j.jcin.2012.07.019.

From Luigi Sacco University General Hospital, Cardiovascular Department, Milano, Italy (G.G., C.R., A.M., M.C., C.A.); Forcardio.Lab, Fondazione per la Ricerca in Cardiocirurgia ONLUS, Milano, Italy (G.G., C.R., R.V., A.M., M.C., B.F.G., C.A.); DEIB Politecnico di Milano, Milano, Italy (R.V., A.M., B.F.G.); and Università degli studi di Milano, Milano, Italy (C.A.).

Correspondence to Claudia Romagnoni, MD, Cardiovascular Surgery Department, "Luigi Sacco" University General Hospital, Via G. Grassi 74, 20157 Milan, Italy. E-mail clau.romagnoni@hotmail.it



**Figure.** Mitral double orifice after transcatheter edge-to-edge repair. Direct left atrium (A) and left ventricle (B) views and corresponding 3-dimensional echographic image (C).

## Movie Legend

**Movie 1.** Intracardiac visualization of the implant in physiologic conditions. Recommended application: VLC.

**Movie 2.** Intracardiac visualization of the implant for treatment of P2 mitral flail. Recommended application: VLC.