

# Aortic Flow and Morphology Adaptation to Deconditioning after 21-Days of Head-Down Bed-Rest Assessed by Phase Contrast MRI

Enrico G. Caiani<sup>1</sup>, Giovanni Riso<sup>1</sup>, Federica Landreani<sup>1</sup>, Alba Martin-Yebra<sup>1,2</sup>, Selene Pirola<sup>3</sup>, Filippo Piatti<sup>1</sup>, Francesco Sturla<sup>1</sup>, Pierre Vaida<sup>4</sup>, Pierre-Francois Migeotte<sup>5</sup>

<sup>1</sup> Dipartimento di Elettronica, Informazione e Bioingegneria, Politecnico di Milano, Italy

<sup>2</sup> Instituto de Investigación en Ingeniería de Aragón (I3A), Universidad de Zaragoza, Spain

<sup>3</sup> Department of Chemical Engineering, Imperial College, London, UK

<sup>4</sup> École Nationale Supérieure de Cognitique, Institut Polytechnique de Bordeaux, France

<sup>5</sup> Université Libre de Bruxelles, Bruxelles, Belgium

## Abstract

*Our aim was to assess the effects of 21-days head-down (-6 degrees) bed-rest (BR) and effectiveness of sledge jump countermeasure (CM), on aortic flow and morphology by Phase Contrast (PC) MRI. Male subjects were enrolled at :envihub (DLR, Germany) in control (CTRL, N=12) or countermeasure (CM, N=12) groups. PC-MRI images were obtained before and after 21-days of BR, and analyzed with custom software. Semi-automated region growing and thresholding were applied to segment the aortic lumen, and to compute parameters from velocity images: area lumen (AL), flow velocity, stroke volume (SV), flow rate (Qpeak), time-to-peak flow, systolic duration and heart beat duration (RR). After 21 days, in CTRL significant decreases in SV (14%), Qpeak (5%) and AL (4%) were observed compared to baseline values. Conversely, for CM no changes were observed in these parameters, but only in RR (-8%). Cardiac adaptation to deconditioning due to immobilization resulted in a reduction of SV and Qpeak that might have induced a remodeling process in the ascending aorta, by shrinking of its lumen. The applied CM seemed to counteract at least partially these effects.*

## 1. Introduction

The weightlessness environment experienced by astronauts on orbit is known to cause fluid shift from the lower to the upper body, thus altering central filling volumes and pressures [1]. These hemodynamic alterations, that elicit a series of other changes in the human body to reach a new homeostasis condition, directly influence cardiac chamber dimensions and

function, with a decrease in stroke volume and cardiac load, and left ventricular (LV) remodeling once permanence in space is prolonged for some months.

As these changes are often associated with adverse effects in astronauts associated with post-flight orthostatic intolerance [2], thus potentially precluding their performance once returning in a partial or 1g environment, it becomes important to better understand cardiac physiology in space and to design and test specific countermeasures (CM) to reduce the impact of these adverse effects.

In this perspective, the 6° head-down tilt bed rest (HDBR) represents a unique opportunity for performing ground based-studies in which to evaluate the effects of prolonged space flight on the cardiovascular system and testing the efficacy of CM. HDBR represents a model of chronic circulatory unloading, simulating sustained exposure to microgravity that mimics the changes in the body similar to what reported during space-flight [3].

We hypothesized that prolonged immobilization (21 days or more) induced by HDBR could lead to changes not only to the heart but also to big vessels such as aorta, by functional modifications that could have an impact on its morphology.

In fact, the effect of blood flow on the vascular endothelium, related to the local wall shear stress, has been proposed to be a critical determinant of vascular disease progression in atherosclerosis and aneurysms [4].

To image the heart, magnetic resonance imaging (MRI) is considered the gold standard tool for both anatomy and function, for its non-invasiveness and ability to provide high-quality images in any anatomical orientation.

In addition, 2D Phase Contrast MRI (PC MRI) is an established technique able to provide blood flow in-vivo

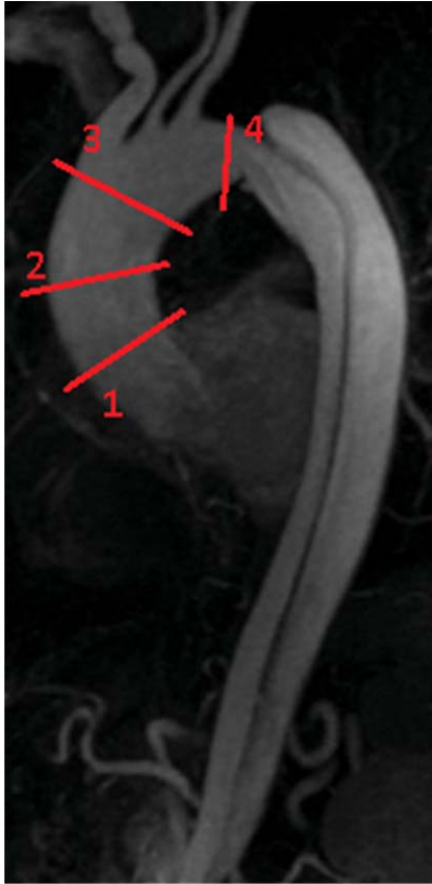

Figure 1. Longitudinal scan of the aorta with highlighted in red the cross-sections in which PC-MRI has been acquired

assessment in a specific cross-sectional plane by the acquisition of MRI magnitude complemented by three modulated gradients inducing phase offsets between  $\pm \pi$  to moving protons [5]. Their motion is then encoded into velocity data along three orthogonal directions, thus generating a full 4D velocity-map (3D spatial + 1D time) of the specific anatomical cross-section of interest. Accordingly, our hypothesis was to study aortic flow and morphology using phase-contrast magnetic resonance imaging (PC-MRI) during HDBR. In addition, the effectiveness of a novel sledge jump system countermeasure was evaluated.

## 2. Methods

### 2.1. Experimental design

As part of the European Space Agency (ESA) HDBR



Figure 2. Example of the acquired delta phase in the head-to-foot direction for the aortic cross-sectional plane at position 1.

strategy, an only male population composed by 24 healthy volunteers (mean age  $30 \pm 6$ , mean height  $181 \pm 6$  cm, mean weight  $77 \pm 6$  kg) were recruited after multiple screening and psychological tests. Subjects had no history of cardiovascular disease and were not taking medications of any kind. Each subject provided written, informed consent that was approved by the Institutional Review Board of the Deutsches Zentrum für Luft- und Raumfahrt (DLR).

Subjects were assigned randomly to a sedentary control group (CTRL) or to a treatment group (CM) for a 60-days HDBR. They were admitted at the :envihub (DLR, Koln, Germany) to get acclimated to the bed rest for 14 days before initiating uninterrupted HDBR, monitored 24h a day, and provided with strictly controlled diet aimed at preventing body weight changes. After completing the HDBR portion of the study, subjects remained in the facility for an additional 15 days for further testing. In the ambulatory periods preceding and following HDBR, lying in bed during the day was not allowed.

The CM group underwent a sledge jump protocol in 48 days out of 60 days, including warm-up and three maximal countermovement jumps (CMJ) at 80% of body weight (BW), four series of 12 CMJs each, and two series of 15 hops each at 85% body weight.

### 2.2. PC-MRI protocol and analysis

MRI acquisitions were performed 4 days before the HDBR start (BCD-4), during the 21<sup>st</sup> and the 58<sup>th</sup> day of HDBR (HDT21 and HDT58, respectively) and 5 days after the termination of the HDBR (R+4).

The subject was placed inside the MRI machine (Biograph mMR, Siemens) positioned at 0° directly from his bed. Several sequences were applied to study cardiac chambers anatomy and function. In particular, 2D PC-MRI images with interleaved three-directional velocity

encoding (VENC: x and y: 80 cm/s; z: 150 cm/s) were obtained transecting the ascending aorta at different levels (30 frames/cardiac cycle, spatial resolution  $1.4 \times 1.4 \times 5 \text{ mm}^3$ ), during spontaneous breathing and pulse pressure gating (see Figure 1).




Figure 3. Example of the segmented aortic lumen and resulting color-coded magnitude velocity information

PC-MRI images (Figure 2) were analyzed with a custom-developed tool [6], completely implemented in Matlab (The MathWorks Inc., Natick, MA, United States), that allowed extraction of the cartesian velocity components ( $v_x$ ,  $v_y$ ,  $v_z$ ) from delta phase images along the three orthogonal directions ( $x$ ,  $y$ ,  $z$ ) (5) to obtain velocity magnitude images. A dedicated segmentation algorithm performing Region Growing and Thresholding (Rg-Th), exploiting texture properties, was applied to segment the aortic lumen and obtain a binary mask corresponding to the aortic lumen on the 2D cross-sectional image in the frame with max magnitude velocity, thus providing the region of interest in which to limit the parameters extraction from velocity images

computation (Figure 3). In particular, the following parameters were computed: area lumen (AL,  $\text{mm}^2$ ), mean velocity (m/s), blood flow rate ( $Q_{\text{peak}}$ , l/min), stroke volume (SV, ml), cardiac output (CO, l/min), systolic duration (ms), cardiac cycle duration (RR, ms).

Statistical analysis was performed to test for differences in respect to BCD-4, and to evaluate the effectiveness of the applied countermeasure.

### 3. Results

Preliminary results relevant to the analysis of the cross-sectional images obtained at position 1, corresponding to the supra-avalvular ascending aorta, will be presented, relevant to the acquisitions performed at BCD-4 and HDT21 in 11 subjects in the CTRL group (one subject did not terminate the study) and in 12 subjects in the CM group.

In the CTRL group, 21 days of HDBR induced significant changes in several parameters compared to baseline value: SV decreased by 14%,  $Q_{\text{peak}}$  was reduced by 5%, and AL shrank by 4%. Hence not significant, systolic duration was shortened by 7% ( $p=.11$ ), while RR and CO were unchanged.

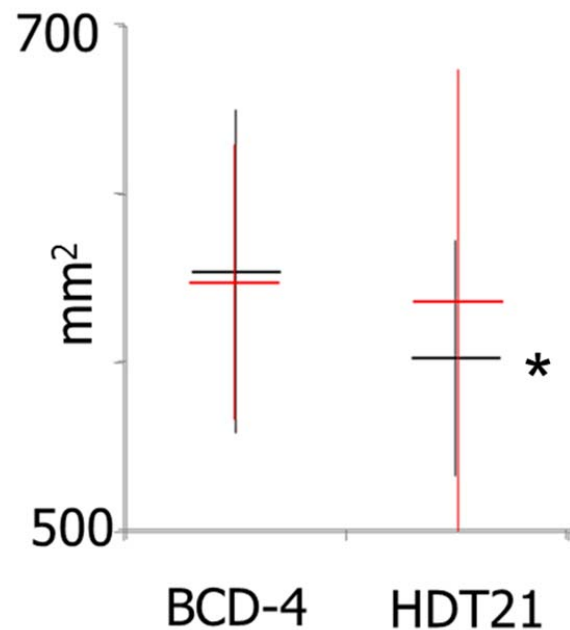


Figure 4. Results relevant to the aortic lumen cross-sectional area for CTRL (in black) and CM (in red) groups, expressed as median and 25<sup>th</sup> and 75<sup>th</sup> percentiles. \*: paired t-test HDT 21 vs BCD-4.

In CM group, the only significant change was in RR, that resulted decreased by 8%, with the systolic duration shortened only by 2.5% ( $p=.09$ ) while only a trend in SV reduction by 8.5% ( $p=.12$ ) was noticed.

#### 4. Discussion

This is the first study addressing aortic morphology and function using PC-MRI during HDBR experiments.

In CTRL group, cardiac adaptation to deconditioning due to immobilization induced by HDBR resulted in both a reduction in SV and shrinking in the aortic lumen of the ascending aorta, already visible after 21 days.

These results are in agreement with what reported even in shorter studies of 5-days HDBR using echocardiographic imaging [7], where SV, aortic peak and mean flow velocity, and velocity time integral were found reduced, while RR and CO were unchanged.

Interestingly, these reductions were accompanied by a shrinking of the aortic lumen internal cross-section, thus opening possible questions about the relation between microgravity and the effect of blood flow on the vascular endothelium [4], with potential changes in local wall shear stress that could determine such anatomical variations.

Conversely, when the sledge jump protocol was applied in the CM group, it appeared able to counteract at least partially these effects.

Further more comprehensive results could be obtained by the analysis of blood flow velocity along the other acquired cross-sectional sections of the aorta, as well as by considering the effects at HDT58, and the ability to restore pre bed rest conditions at R+4.

#### 5. Conclusion

Cardiac adaptation to deconditioning due to 21-days HDBR immobilization resulted in appreciable changes in aortic anatomy and flow. When a sledge jump protocol countermeasure was applied, such changes were not as evident as without, thus suggesting a potential effectiveness of the applied CM.

#### Acknowledgements

We are extremely grateful to all the personnel of ESA and DLR involved in the bed rest studies for the support to the realization of our experiment, as well as to the experimental subjects for their dedicated collaboration. This research has been performed thanks to the contribution of the Italian Space Agency (contracts

2013/032/R.0 – AEQUABED, and 2013/64/R.0 – 3D Ballistocardiography in microgravity, recipient Dr. EG Caiani). A.Martin-Yebra was partially supported by CIBER-BBN through Instituto de Salud Carlos III and FEDER (Spain), project TEC2013-42140-R funded by MINECO and FEDER, and by Gobierno de Aragón and European Social Fund (EU) through BSI CoSGroup (T96). S Pirola is recipient of ITN H2020 Marie Skłodowska Curie. P Vaïda research was funded by Centre National d'Études Spatiales (CNES) (contractCNES/4800000632). P-F. Migeotte is supported by the Belgian Federal Science Policy via the European Space Agency PRODEX program (PEA 4000110826).

#### References

- [1] Charles JB, Bungo MW. Cardiovascular physiology in space-flight. *Exp Gerontol* 1991;26: 163–168.
- [2] Guell A, Braak L. Cardiovascular deconditioning syndrome during space flight. *Ann Cardiol Angeiol (Paris)* 1989;38: 499–502.
- [3] Arbeille P, Fomina G, Roumy J, Alferova I, Tobal N, Herault S. Adaptation of the left heart, cerebral and femoral arteries, and jugular and femoral veins during short- and long-term head-down tilt and spaceflights. *Eur J Appl Physiol* 2001;86: 157–168.
- [4] Potters WV, van Ooij P, Marquering H, van Bavel E, Nederveen AJ. Volumetric arterial wall shear stress calculation based on cine phase contrast MRI. *J Mag Res Imag* 2015;41(2):505–516.
- [5] Bernstein MA, King KF, Zhou XJ. *Handbook of MRI Pulse Sequences*. Elsevier, 2004.
- [6] Pirola S, Piatti F, Sturla F, Votta E, Nesteruk I, Lombardi M, Della Corte A, Bissell M, Redaelli A, Caiani E. Phase Contrast MRI: development of a user-friendly platform for fast-automated segmentation and fluid-dynamic post-processing. *CIC* 2015;42:717-720.
- [7] Caiani EG, Massabuau P, Weinert L, Vaïda P, Lang RM. Effects of 5 days of head-down bed rest, with and without short-arm centrifugation as countermeasure, on cardiac function in males (BR-AG1 study). *J Appl Physiol* 2014;117(6):624-632.

#### Address for correspondence:

Enrico G Caiani

Dipartimento di Elettronica, Informazione e Bioingegneria  
Politecnico di Milano, Piazza L. da Vinci 32, Milano, Italy  
E-mail: enrico.caiani@polimi.it