

Quantification of myocardial viability in late Gadolinium enhancement Cardiac MRI

M. Chiara Carminati¹, Cinzia Boniotti², Mauro Pepi¹, Enrico G. Caiani²

¹Centro Cardiologico Monzino, IRCCS, Milano, Italy

²Dipartimento di Elettronica, Informazione e Bioingegneria, Politecnico di Milano, Milano, Italy

Abstract

We propose an approach to quantify myocardial viability from late Gadolinium enhancement Cardiac Magnetic Resonance (LGE-CMR) images in patients with ischemic cardiomyopathy.

After manual delineation of myocardial borders, segmentation of myocardial scar tissue is performed automatically by applying a classifier based on Gaussian mixture model (GMM) of the myocardium intensity histogram. Segmentation result is refined based on the a priori knowledge of the hyper-enhanced pattern of LGE-CMR in ischemic patients, and a dedicated parametric dense representation of scar transmuralit

y is proposed. High level of accuracy and correlation against the manual reference technique envisage the clinical applicability of automated processing technique, minimizing user interaction and the time required for the analysis.

1. Introduction

Late Gadolinium enhancement cardiac magnetic resonance (LGE-CMR) is the standard imaging technique for the assessment of left ventricular (LV) myocardial viability, allowing the identification of scar tissue [1,2]. With this procedure, a Gadolinium-based contrast agent is injected and after 10-20 minutes a single-frame sequence is acquired, when the agent is washed-out by normal tissue, resulting in hyper-enhanced (HE) intensity in nonviable myocardial tissue when compared to the darker normal myocardium.

The presence of this HE tissue has an important prognostic and therapeutic value, as it is a strong predictor of LV remodeling, cardiac dysfunction and mortality [2-4]. However, a recognized optimal method for LV viability quantification is still not defined, so that in clinical practice the qualitative evaluation is commonly adopted, together with manual or more rarely semi-automatic quantitative technique [5].

Our first aim was to evaluate the performance of an automated method for HE myocardial tissue segmentation in ischemic patients against scar manual tracings, considered as the reference technique. We furthermore

aimed to test the effect of deriving segmentation parameters by considering simultaneously all the images belonging to the short-axis (SA) stack (global approach), compared to obtaining the same parameters from each single slice (single-slice approach) separately, as it was previously proposed. Finally, we propose a dedicated parametric representation for the local quantification of myocardial scar transmuralit

2. Materials and Methods

2.1. Segmentation technique

The first step of the proposed analysis was the manual tracings of the endocardial and epicardial borders, in order to identify the myocardial region in each image. Cine images with corresponding slice position and cardiac phase were displayed as reference alongside the LGE image to be contoured. Then, the segmentation technique adopted for detection of HE area within the myocardium was automated and based on Gaussian mixture model (GMM) classifier [6]. The GMM is a clustering method, which classifies the myocardial pixels in 3 groups: normal, border zones (BZs) and HE. BZs are defined as peri-infarct areas surrounding scars characterized by higher intensity values than normal myocardium, but lower than nonviable tissue. The classification process is performed by fitting the intensity histogram of the myocardial region with three Gaussian distributions, one for each class, whose mean intensity and variance are estimated by an expectation/maximization approach [6]. The two intersections between the three Gaussian distributions represent the threshold values used for discriminating between normal myocardium and BZs, and between BZs and HE, as shown in Fig.1. The segmentation of BZs, although rarely performed, might be of clinical importance, as their presence was suggested to be a powerful predictor for ventricular arrhythmic events and post-infarction mortality [7].

The segmentation scheme was applied twice. In the first scenario, called single-slice approach, the GMM clustering was applied at each SA image showing HE tissue, separately. Even though the segmentation scheme

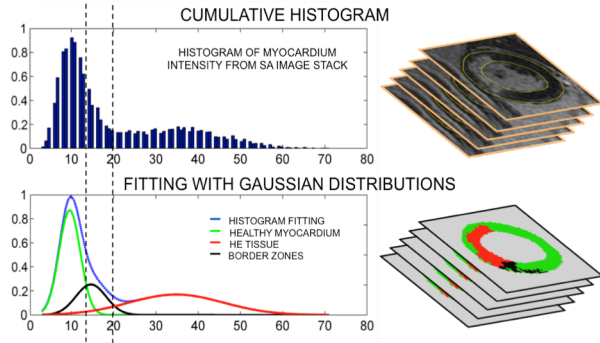


Figure 1. Gaussian mixture model classification applied in the global approach. Top: intensity histogram of the myocardial region. Bottom: the intensity histogram (blue line) is modeled by fitting three Gaussian curves (green, black and red). From the intersection of these curves, the threshold intensities separating healthy myocardium from border zones, and border zones from hyper-enhanced regions, are defined and then applied to the myocardial region to obtain a parametric map, showing the healthy myocardium (green), the HE scar (red), and the border zone (black).

is automated, images without HE area were not analysed, as the algorithm requires the presence of HE tissue to correctly discriminate the three different classes. In the second scenario, the global approach, the GMM clustering was applied simultaneously on all pixels of the myocardium in all SA images of the stack. Potential advantage of this approach is the increase of analysis automation, as no user interaction is needed to select images with HE areas.

In both cases after the application of GMM classifier, the following post-processing steps were applied to refine segmentation results. First, regions classified as HE were removed if their area was less than 5% of the total myocardial area, likely representing noise. Furthermore, small dark areas surrounded by HE regions, potentially representing microvascular obstructions, were included in the HE region. Finally, thin regions classified as HE connected to the epicardium or to the endocardium were removed because potentially related to incorrect myocardial border delineation.

The definition of these thin regions was made by computing the following threshold value:

$$tr = \frac{\#MB \text{ pixels}}{\#ScA \text{ pixels}} * 100[\%]$$

where #MB pixels is the number of pixels connected to the myocardial border and #ScA pixels is the number of pixels constituting the scar area, thus measuring for each segmented scar the percentage of pixels connected to one myocardial border with respect to the total scar size. Segmented scars connected to one myocardial border were removed if their tr index reached the following cut-

off values: 100% for the endocardium, meaning that all pixels belonging to the scar are connected to the endocardial border, and 50% for scar connected to the epicardium. These values were empirically set, according to the rationale that classification errors are more prone to happen where segmented scars are connected to the epicardium, as scar position is expected to be sub-endocardial in ischemic patients.

This operation made it possible to remove pixels belonging to the blood pool or to the epicardial fat regions that might be erroneously classified as nonviable tissue if included in the myocardium during myocardial borders delineation, as their intensity is comparable to scar tissue.

2.3. Quantification of scar size and transmuralty

After segmentation, the quantification of scar extent was estimated by computing the following indices:

- scar mass, i.e. the total volume of the nonviable tissue per slice, as sum of pixels in the HE area multiplied by the slice thickness, multiplied by the myocardial density (1.05 g/cm^3);
- percent scar, i.e. the HE area for all SA images divided by the total amount of LV tissue (i.e. the area within the endocardial and epicardial contours for all images belonging to the SA stack);
- transmuralty (T), i.e. the percentage extension of nonviable tissue in the radial direction from the endocardium to the epicardium.

To compute T , each SA image was sampled with 2.5° equally spaced line segments radially oriented from the center of the LV, estimated as the centroid of the region delimited by the epicardium. For each line segment, T was then computed as the ratio between the radial length of the segmented scar and the myocardial local radial extension (Fig. 2).

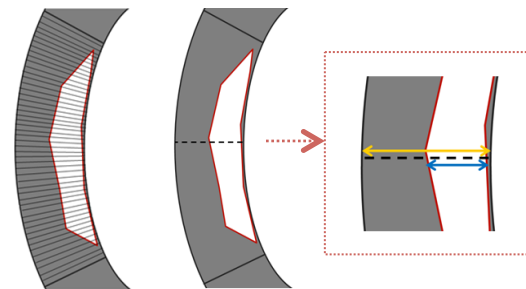


Figure 2. Schematic representation of transmuralty computation: a myocardial sector with a scar region is sampled with radial profiles. Transmuralty is computed for each profile as the ratio between the scar width (blue arrow) and the myocardium width (orange arrow).

This information was then parametrically represented in a dedicated bull's eye model, where all SA slices in the stack are represented individually. Furthermore, each sampling profile is represented by visualizing the local value of T, according to a color-coded percentage scale ranging from 0% to 100% (Fig. 3).

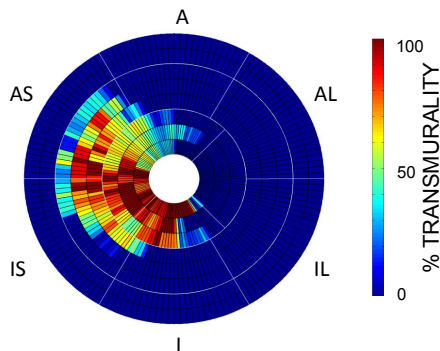


Figure 3. Bull's eye high density: parametric representation of local transmural percentage.

2.4. Imaging data

Cardiac MRI-LGE images of 10 retrospectively selected patients (8 male, age 63 ± 12 years) with previous myocardial infarction referred for the evaluation of LV function were considered for the analysis. ECG-triggered SA images were acquired during consecutive breath-holds using GR scanning sequence (1.5T GE scanner, 256×256 matrix size, pixel spacing 1.4844×1.4844 mm, slice thickness 8 mm, no overlap, no gap), 10-20 min after an intravenous bolus of 0.1 mmol/kg Gadolinium-gadobenate dimeglumine (Multihance-Bracco, Milan, Italy). Inversion time was individually adapted during acquisition to ensure intensity homogeneity between slices (usual range 220-300 ms). The study was approved by the institutional review board, and each patient gave her/his informed consent.

2.4. Validation protocol

Manual tracings of the HE scar regions in each SA image was chosen as the reference technique for the evaluation of the algorithm performance. The same manually traced endo- and epicardial borders were used for both the GMM and manual analyses.

Algorithm performance was evaluated by comparing segmentation results with the reference manual technique, for both the single slice and the global approach. The correct identification of HE tissue presence was assessed by computing sensitivity, specificity and accuracy for the custom bull's eye representation by evaluating the presence of HE tissue in each radial profile.

The correct quantification of scar extension, measured as scar mass and percent scar, both for the single and

global approach, was furthermore verified by linear correlation and Bland-Altman analyses against the manual technique. To allow for results comparison with the manual technique, BZs detected by the GMM segmentation were considered as normal myocardium in the analysis.

3. Results

As expected, all patients showed HE tissues: 83 SA slices were overall analyzed and 73.5% (61/83) had scars; the number of slices with HE for each patient was in the range of 28.6% (2/7) -100% (10/10).

Exemplary results are presented in Fig. 4. Scar segmentation on one representative patient obtained with the reference manual technique and the global approach are shown, with overall very similar scar delineation but with a slight overestimation in the medial slices for the global approach compared to the reference manual technique. On the left, local transmural percentage is illustrated through the bull's eye high density, highlighting the high correspondence between the manual technique and the proposed global approach.

Accuracy analysis showed high values of specificity, sensitivity and accuracy, in both single slice (98.3%, 81.2%, 93.1%, respectively) and global approach (96.1%, 88.6%, 93.8%, respectively), with significantly higher sensitivity for the global approach compared to the single slice ($p < 0.05$, McNemar test). Cohen's K resulted 82.9% for the single slice approach and 85.2% in the global approach, proving high agreement between each approach and the manual technique.

Scar size results in values for scar mass of 14.4 (8.06-19.23) g and 12.7 (10.8-22.6) g, and percent scar values of 16.6 (8.5-31) % and 20.5 (11.1-34)%, expressed as median and interquartile range respectively for single slice and global approach, with no statistical differences between the two approaches ($p < 0.05$, Wilcoxon signed rank test). Correlation and Bland-Altman analysis results are summarized in Table 1. Correlation for scar mass measure was significantly higher for the global approach compared to the single slice approach ($p < 0.05$, Fisher r-to

Table 1. Correlation and Bland-Altman analysis computed for scar mass and percent scar measurements against manual reference technique (*: $p < 0.05$ t-test vs. null; §: $p < 0.05$, Fisher r-to-z transformation).

<i>parameter</i>	<i>approach</i>	r^2	<i>bias</i>	<i>limits of agreement</i>
scar mass	single-slice	0.54	0.26*	-0.86 to 1.4
	global	0.8 [§]	0.64	-0.6 to 0.75
percent scar	single-slice	0.95	6.1*	-21 to 21
	global	0.93	0.89	-8.6 to 10

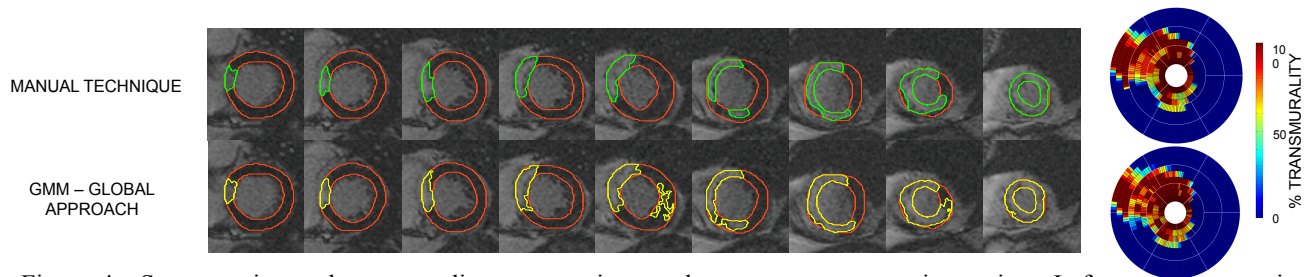


Figure 4. Segmentation and transmuralit y computation results on one representative patient. Left: scar segmentation obtained with the reference manual technique (scar delineated in green) and with the proposed method using the global approach (scar segmented in yellow). Right: transmuralit y parametric representation through the bull's eye high density for both the manual reference technique and the global approach.

-z transformation), with small biases and relative narrow limits of agreement in both approaches. For percent scar measure, very high and similar r^2 were found, again with small biases and relative narrow limits of agreements.

Finally, computational time computed as the time required for the analysis of an entire SA stack, hence small in both approaches, was significantly higher for the single-slice compared to the global approach, with median and interquartile values of 0.79 (0.6-1.5) s and 0.48 (0.31-0.88) s, respectively.

4. Discussion and Conclusions

Although different techniques have been proposed to quantify myocardial non-viable tissue from CMR-LGE images, a recognized optimal method is still not defined and qualitative visual analysis is most often performed in clinical practice. However, the extension of HE scar tissue is able to provide supplementary information beyond conventional risk stratification, thus suggesting that quantitative analysis should be used to measure scar extent and transmuralit y.

We have proposed a comprehensive method for the quantitative analysis of nonviable tissue in CMR-LGE images for patients with ischemic cardiomyopathy, based on automatic segmentation, dedicated post-processing and local transmuralit y quantification. The global approach, analyzing simultaneously the entire SA image stack, lead to faster and reliable results compared to the single-slice approach and the manual reference technique. High level of accuracy and correlation with the reference technique envisage the clinical applicability of the proposed technique, minimizing user interaction and the time required for the analysis.

In this study, a small population was studied and therefore presented results should be considered as a preliminary suggestion. In future research, these results must be verified in a larger cohort and supported by a study of reproducibility.

References

- [1] Kim RJ, Chen E-L, Judd RM. Myocardial Gd-DTPA kinetics determine MRI contrast enhancement and reflect the extent and severity of myocardial injury after acute reperfused infarction. *Circulation* 1996; 94(12): 3318-3326.
- [2] Kim RJ, Fieno DS, Parrish TB, Harris K, Chen E-L, Simonetti O, et al. Relationship of MRI Delayed Contrast Enhancement to Irreversible Injury, Infarct Age, and Contractile Function. *Circulation* 1999; 100(19): 1992-2002.
- [3] Kim RJ, Wu E, Rafael A. The use of contrast-enhanced magnetic resonance imaging to identify reversible myocardial dysfunction. *N Engl J Med* 2000; 343(20): 1445-53.
- [4] Kolipaka A, Chatzimavroudis G, White R, Lieber M, Setser R. Relationship Between the Extent of Non-viable Myocardium and Regional Left Ventricular Function in Chronic Ischemic Heart Disease. *J Cardiovasc Magn Reson* 2005; 7(3): 573-9.
- [5] Schulz-Menger J, Bluemke DA, Bremerich J, Flamm SD, Fogel MA, Friedrich MG, et al. Standardized image interpretation and post processing in cardiovascular magnetic resonance: Society for Cardiovascular Magnetic Resonance (SCMR) board of trustees task force on standardized post processing. *J Cardiovasc Magn Reson* 2013; 15(1): 35.
- [6] Hennemuth A, Friman O, Huellebrand M, Peitgen H. Mixture-Model-Based Segmentation of Myocardial Delayed Enhancement MRI. In *Statistical Atlases and Computational Models of the Heart. Imaging and Modelling Challenges*, LNCS 2013; 7746: 87-96.
- [7] Yan AT, Shayne AJ, Brown K, Gupta SN, Chan CW, Luu TM, et al. Characterization of the peri-infarct zone by contrast-enhanced cardiac magnetic resonance imaging is a powerful predictor of post-myocardial infarction mortality. *Circulation* 2006; 114(1): 32-9.

Address for correspondence.

M. Chiara Carminati
 Centro Cardiologico Monzino, IRCCS
 Via privata Carlo Parea, 4
 Milano, Italy
 E-mail: mcarminati@ccfm.it