



49<sup>TH</sup> **ESAO** & **IFAO** CONGRESS

# Preliminary Assessment of an Innovative Aortic Valve Decalcification Device in Ex Vivo Human Model

F. Perico, E. Salurso, M. Jaworek, F. Pappalardo, E. Fermi, M. Vola, R. Vismara



August 29 - September 1, 2023  
Bergamo, Italy

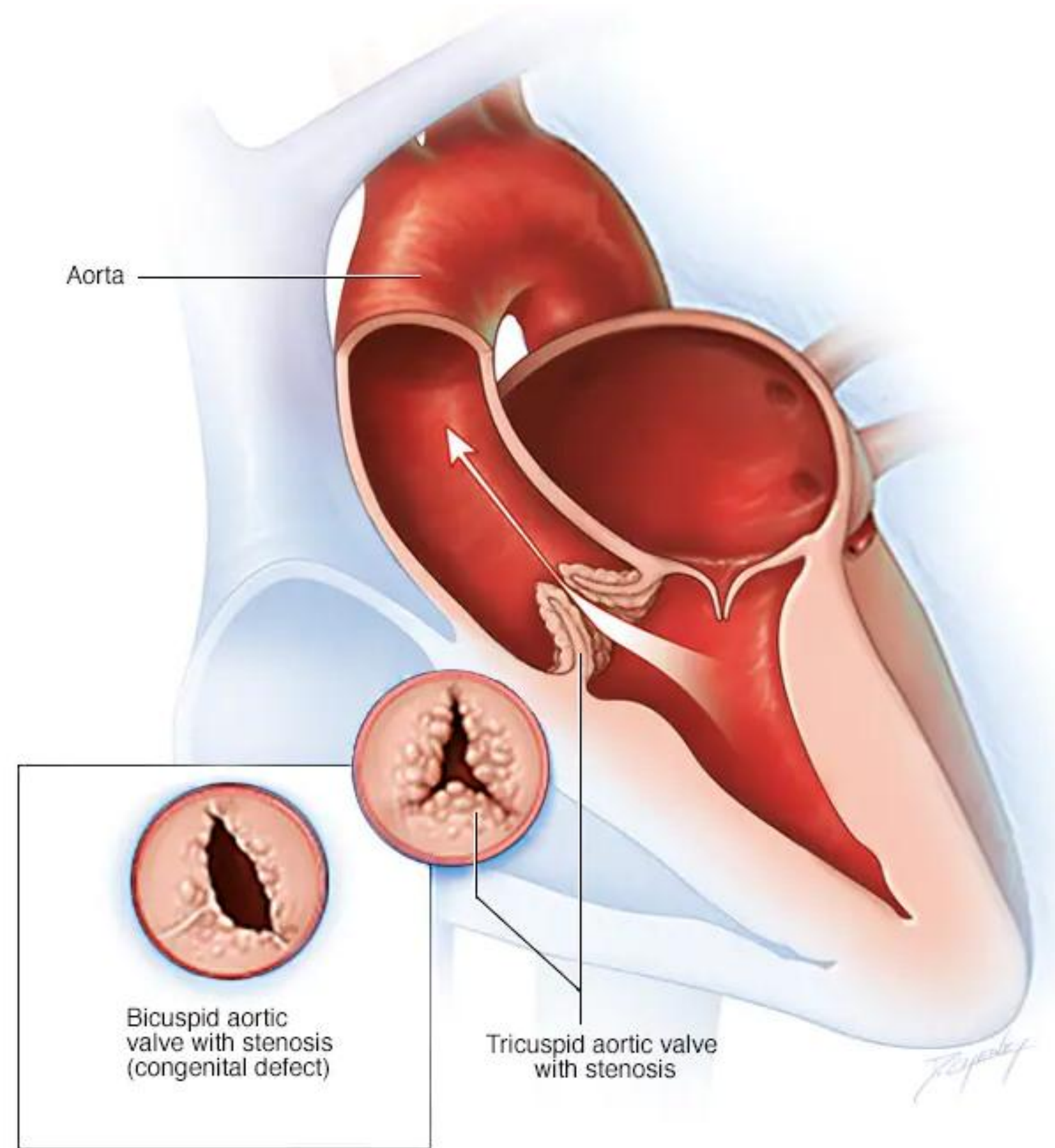
**Marco Vola** has management/advising roles and hold shares in the AorticLab s.r.l. company

## Calcific Aortic Valve Stenosis

4%



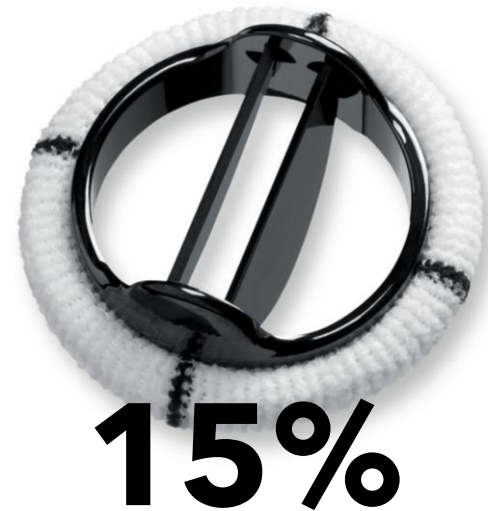of population  $\geq 65$  years old



(Freeman et al. 2005)

## Aortic Valve Replacement

Mechanical Prosthesis



Biological Prosthesis



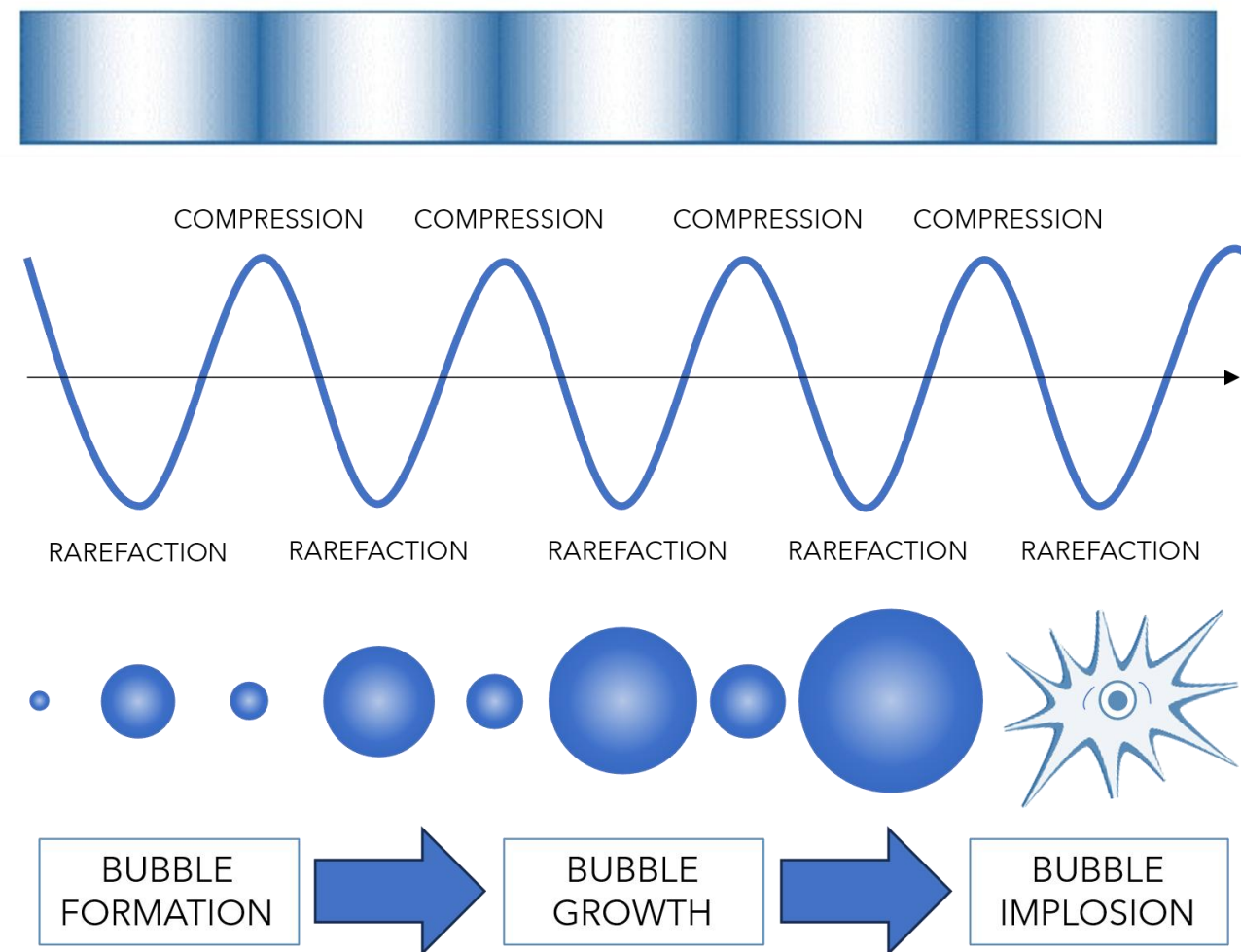
Structural Valve Degeneration

**85%**

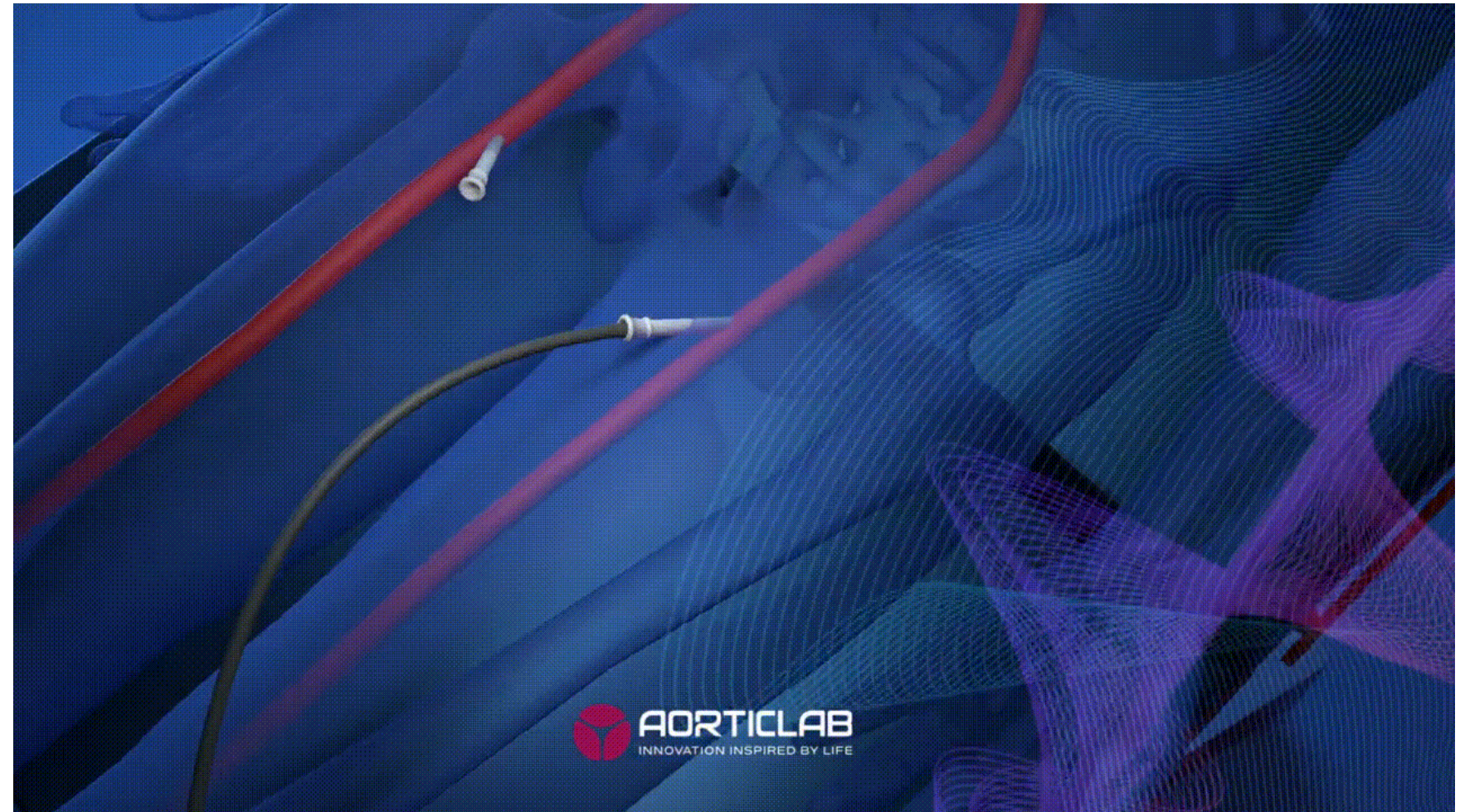
(Norton et al. 2023)

## ULTRASOUND-BASED DECALCIFICATION PROCEDURES

### CAVITATION PHENOMENON



## Transcatheter Debridement Device (TDD)



To **fragment calcium deposits**  
present on the native aortic valves or  
bioprosthetic leaflets

## Research Article

ISSN: 2574-1241



DOI: 10.26717/BJSTR.2021.33.005429

### Trans-Catheter Double-Frequency Ultrasound Ablator for The Treatment of Aortic Valve Leaflets Calcification

Enrico Fermi<sup>1\*</sup>, Davide Benettin<sup>1</sup>, Giacomo Bernava<sup>2</sup>, Maurizio Pesce<sup>2</sup> and Enrico Pasquino<sup>1</sup>

<sup>1</sup>AorticLab S r l, Italy

<sup>2</sup>Unità di ricerca in ingegneria tissutale cardiovascolare, Centro Cardiologico Monzino, IRCCS, Italy

\*Corresponding author: Enrico Fermi, AorticLab S r l, Italy



### Lithotripsy of Calcified Aortic Valve Leaflets by a Novel Ultrasound Transcatheter-Based Device

Giacomo Bernava<sup>1†</sup>, Enrico Fermi<sup>2†</sup>, Guido Gelpi<sup>3</sup>, Stefano Rizzi<sup>1</sup>, Davide Benettin<sup>2</sup>, Marianna Barbuto<sup>1</sup>, Claudia Romagnoni<sup>3</sup>, Domenico Ventrella<sup>4</sup>, Maria Chiara Palmieri<sup>2</sup>, Marco Agrifoglio<sup>5</sup>, Gianluca Polvani<sup>5</sup>, Maria Laura Bacci<sup>4</sup>, Enrico Pasquino<sup>2</sup> and Maurizio Pesce<sup>1\*</sup>

<sup>†</sup>Unità di Ingegneria Tissutale Cardiovascolare, Centro Cardiologico Monzino, Istituto di Ricovero e Cura a Carattere Scientifico (IRCCS), Milan, Italy, <sup>2</sup>AorticLab S.r.l., Bioindustry Park, Colliero Giacosa, Italy, <sup>3</sup>ASST Fatebenefratelli Sacco, Milan, Italy, <sup>4</sup>Università Degli Studi di Bologna, Bologna, Italy, <sup>5</sup>Università Degli Studi di Milano, Milan, Italy



Calcium deposits rupture

## EX VIVO STUDY ON HUMAN HEARTS

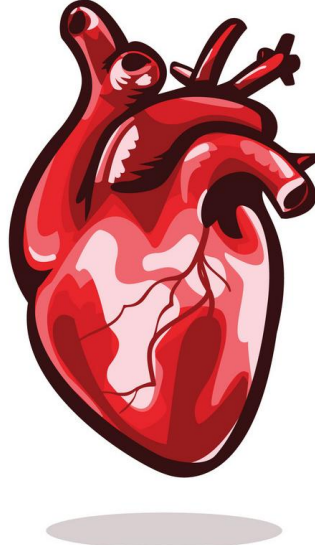
To quantify how the **TDD treatment affects** stenotic aortic **valve hemodynamics**



## QUALITATIVE HISTOLOGICAL ANALYSIS

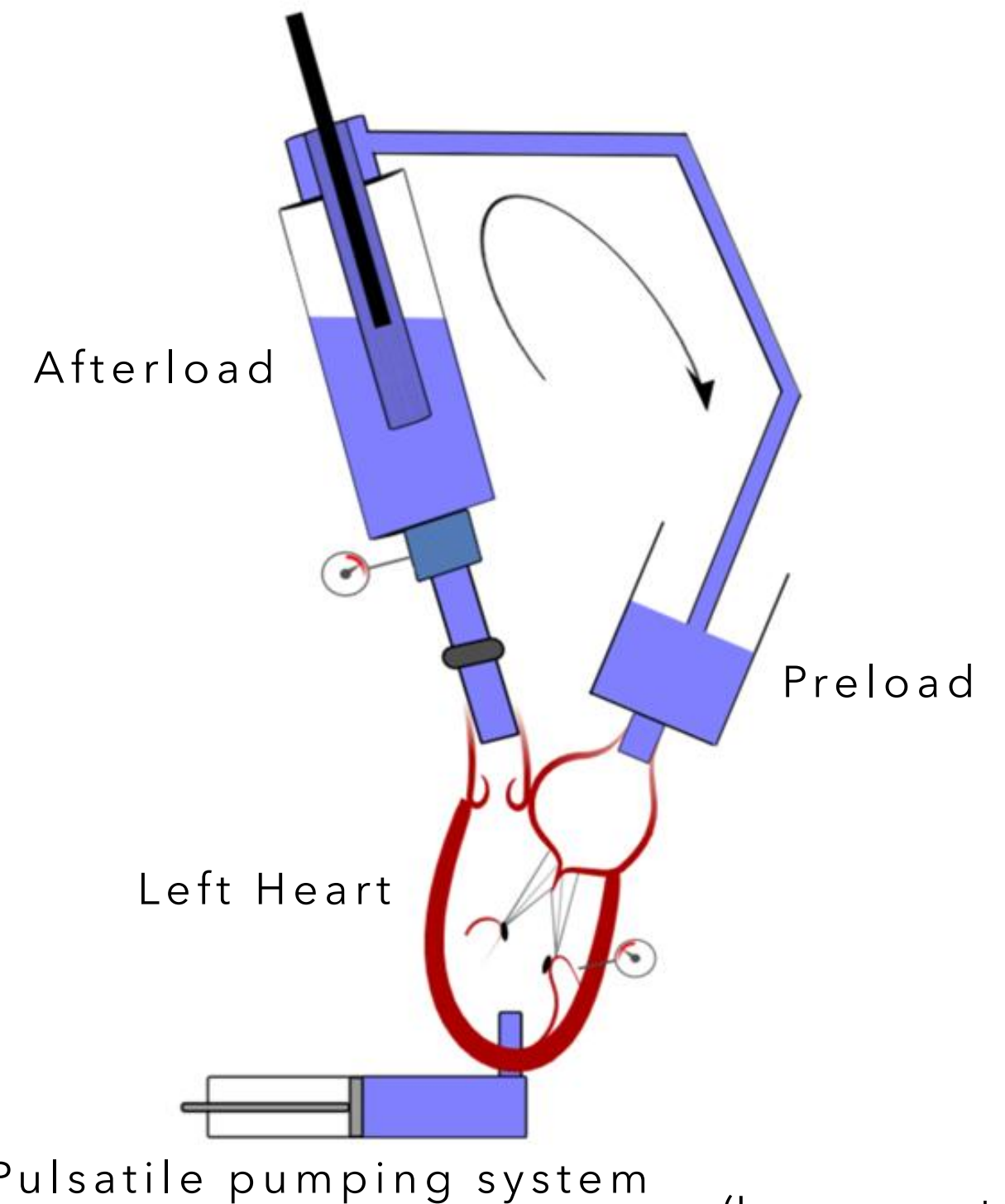
To assess if the **TDD treatment** could alter or **affect** the **structure of valve's leaflets**

3 x  
CADAVERIC  
STENOTIC HEART



EX VIVO PULSATILE FLOW  
CHARACTERIZATION

**Before / After**  
TDD treatment



(Lanzarone et al. 2009)

## INPUT

- Heart Rate: **60bpm**
- Mean Aortic Pressure: **50mmHg**

## OUTPUT

- Ventricular Pressure
- Aortic Pressure
- Aortic Flow

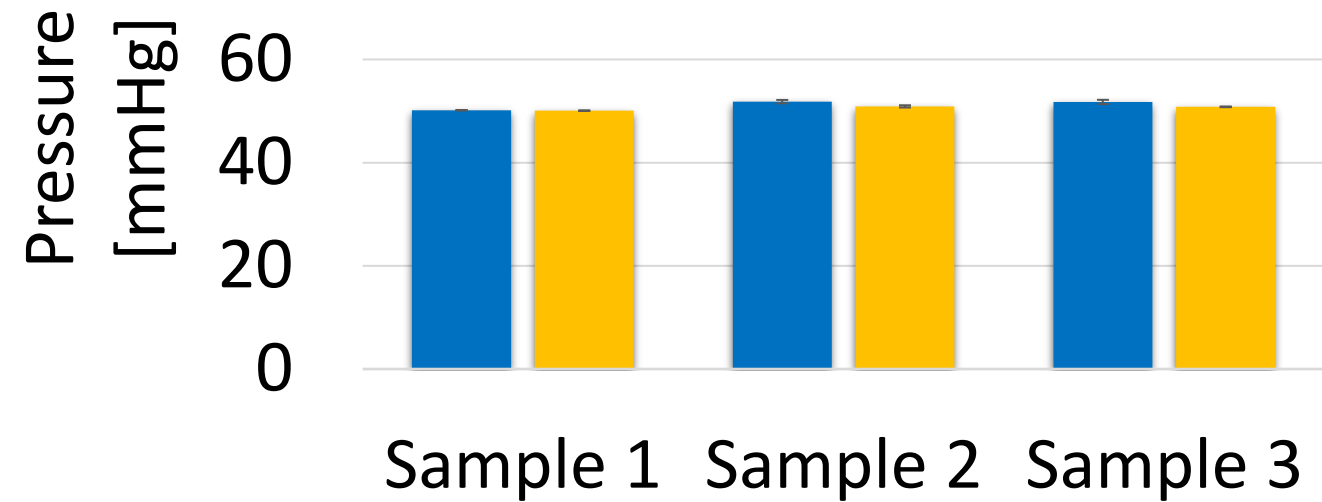
# RESULTS

## Hemodynamics assessment

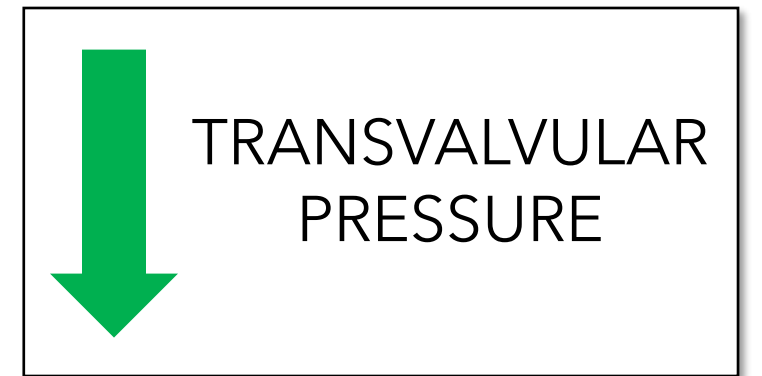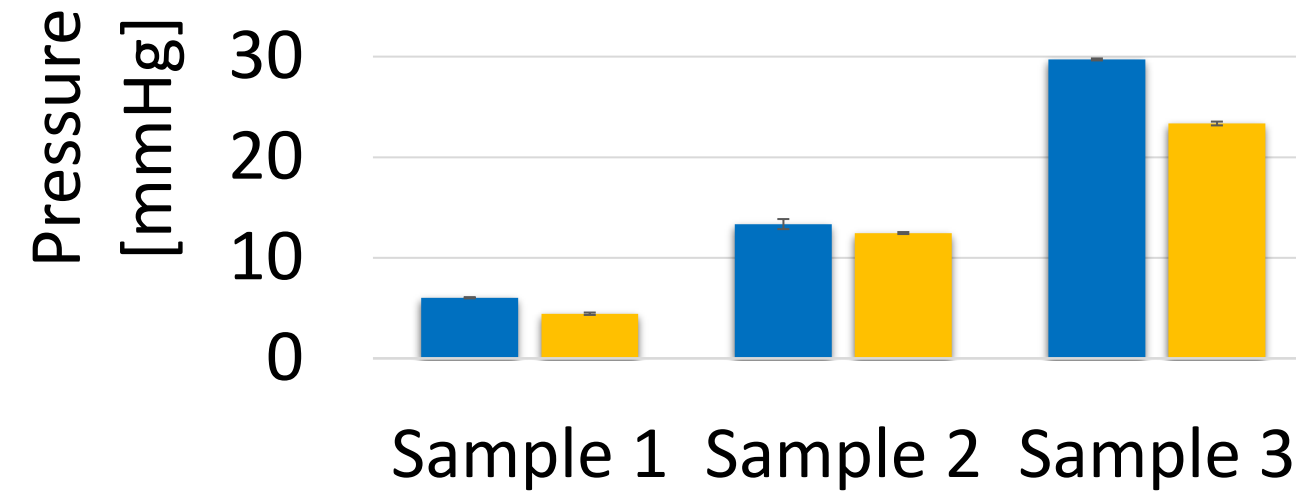
### Working conditions assessment

### Performance indexes assessment

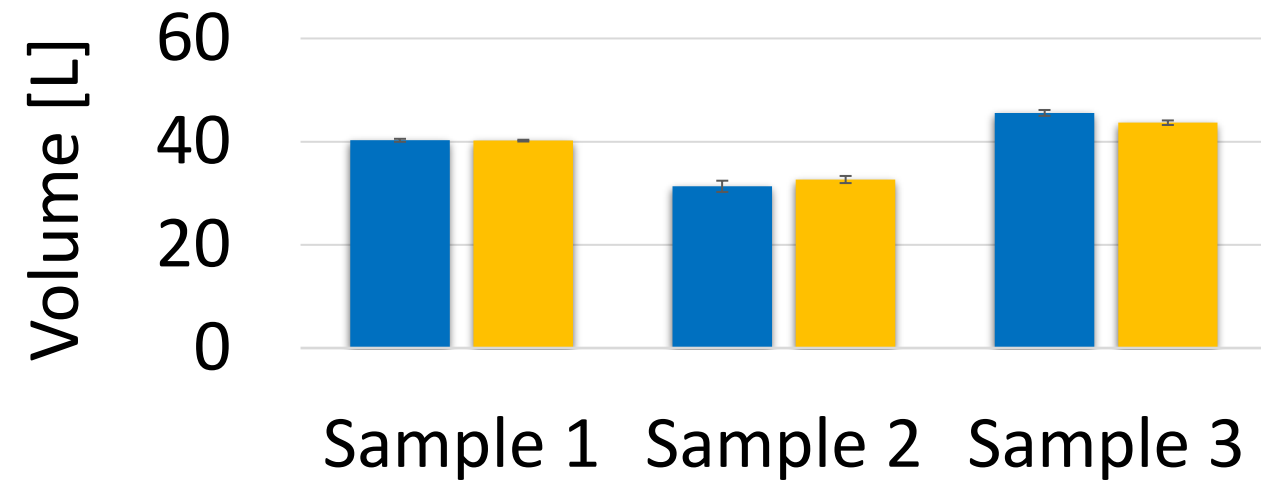
#### MEAN AORTIC PRESSURE




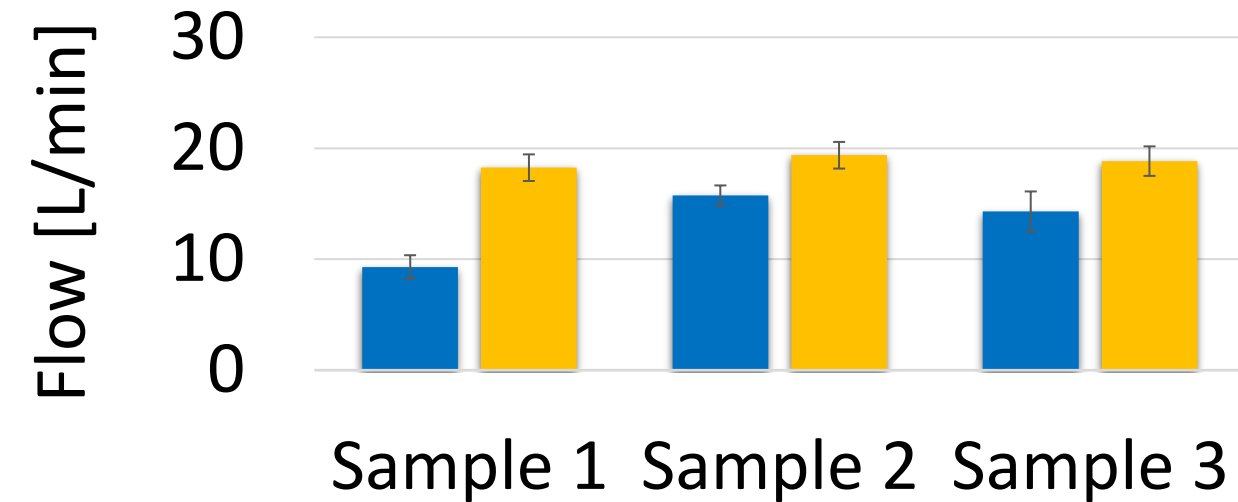
#### TRANSVALVULAR PRESSURE



#### STROKE VOLUME



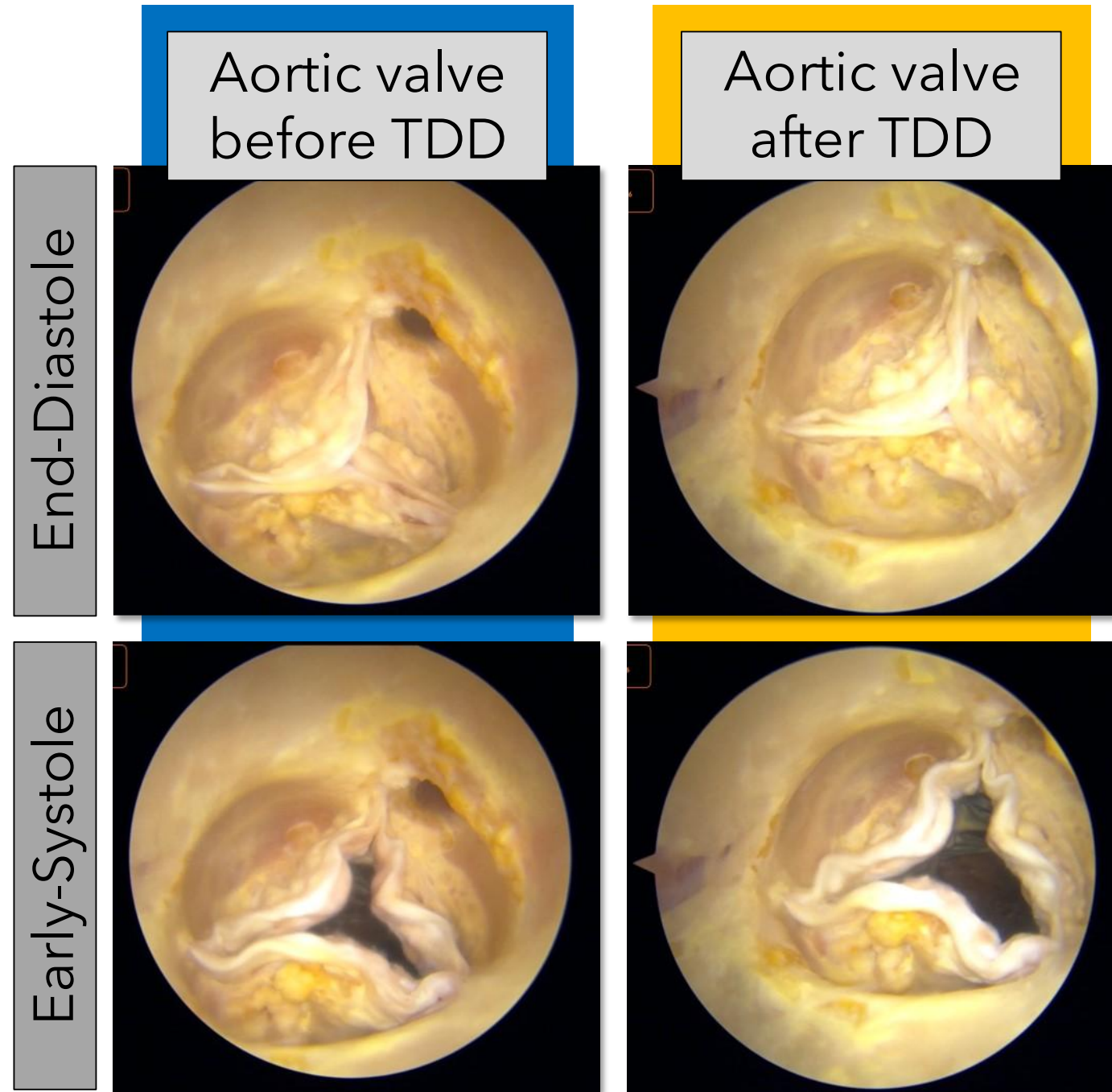
#### BACKFLOW



■ Before TDD    ■ After TDD

■ Before TDD    ■ After TDD

# RESULTS



Endoscope images

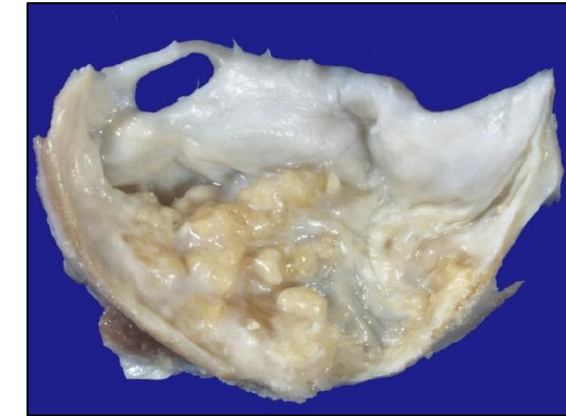
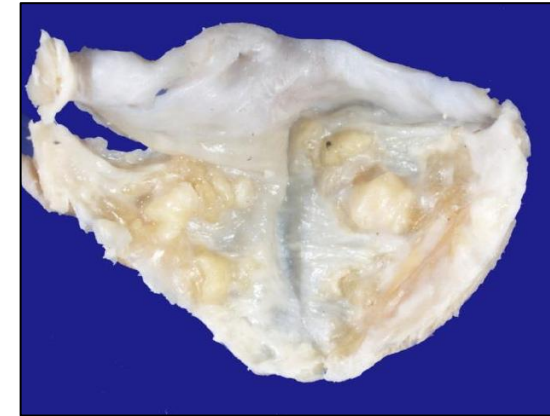
no major damage to aortic valve tissues

## Histological assessment

Control sample

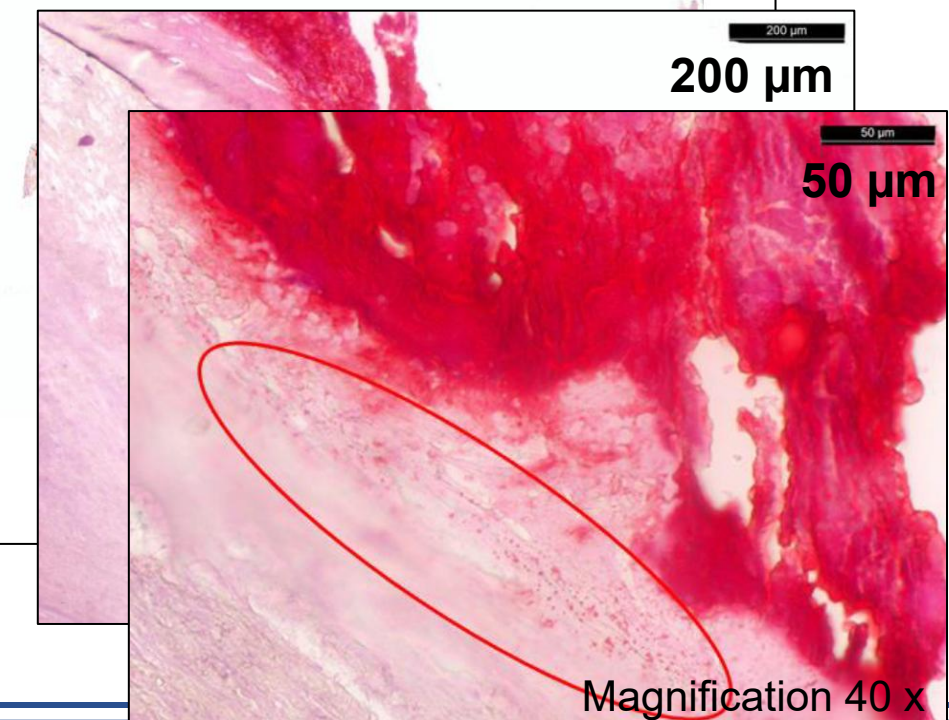
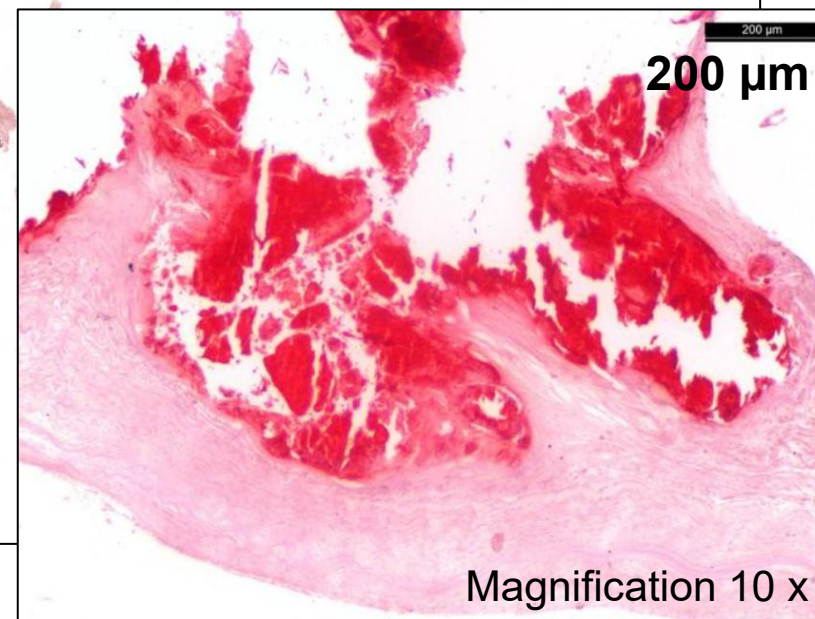
Treated sample

Macroscopic Analysis



Microscopic Analysis

Alizarine Red S


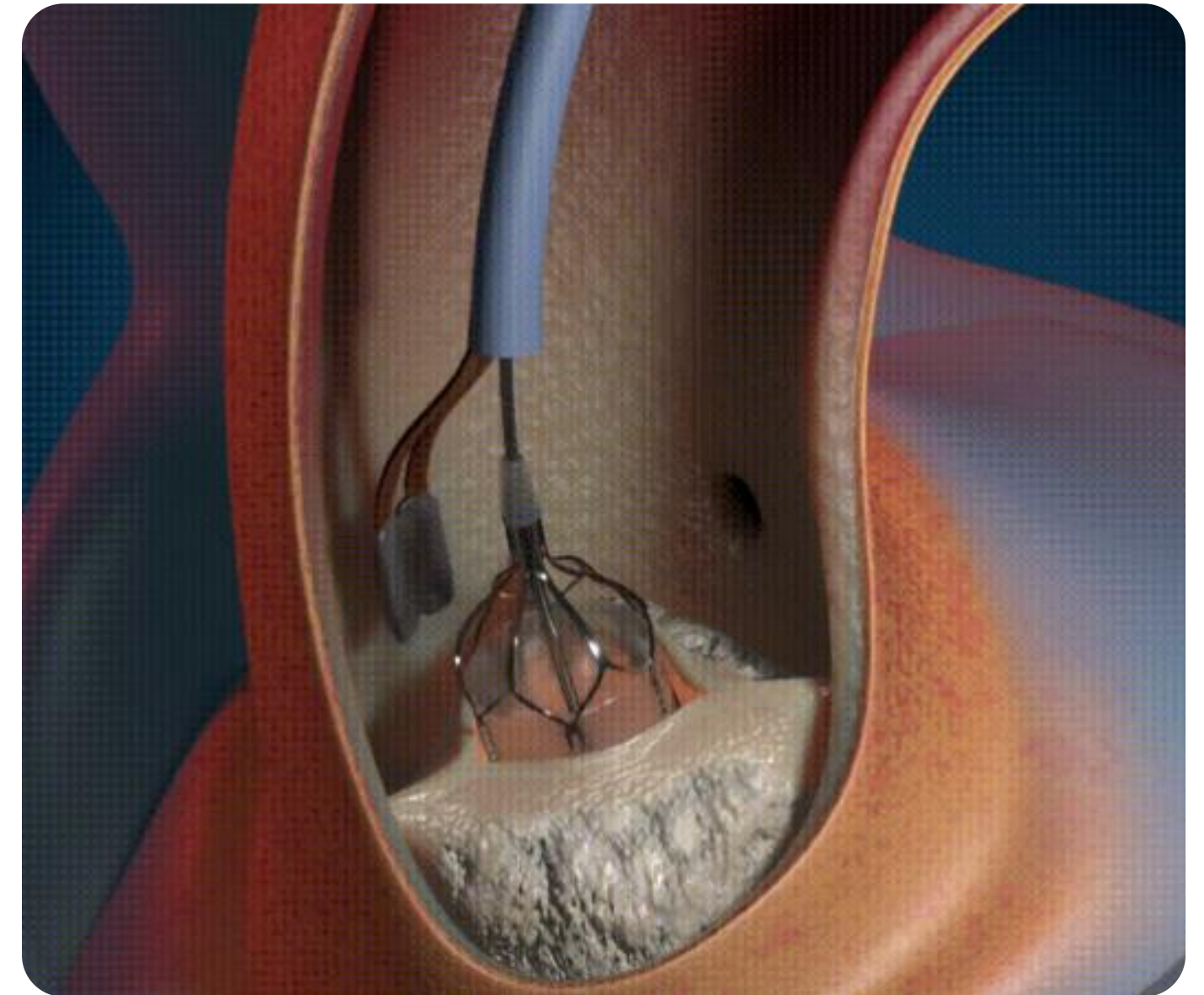


# CONCLUSIONS

Fluid dynamics improvements during systole

No evidence of damage to aortic valve tissues

**TDD** MAY BE CONSIDERED  
A **PROMISING TOOL** TO  
TREAT PATIENTS WITH  
AORTIC VALVE STENOSIS



- Freeman RV, and Otto CM (2005). Spectrum of calcific aortic valve disease: Pathogenesis, disease progression, and treatment strategies. *Circulation*, vol. 111, no. 24, pp. 3316-3326.
- Fermi E, Benettin D, Bernava G, Pesce M, Pasquino E (2021). Trans-Catheter Double-Frequency Ultrasound Ablator for The Treatment of Aortic Valve Leaflets Calcification. *Biomed J Sci & Tech Res* 33(4)-2021. BJSTR. MS.ID.005429
- Bernava G, Fermi E, Gelpi G, Rizzi S, Benettin D, Barbuto M, Romagnoni C, Ventrella D, Palmieri MC, Agrifoglio M, Polvani G, Bacci ML, Pasquino E and Pesce M (2022). Lithotripsy of Calcified Aortic Valve Leaflets by a Novel Ultrasound Transcatheter-Based Device. *Front. Cardiovasc. Med.* 9:850393. doi: 10.3389/fcvm.2022.850393
- Norton EL, Ward AF, Tully A, Leshnower BG, Guyton RA, Paone G, Keeling WB, Miller JS, Halkos ME and Grubb KJ (2023). Trends in surgical aortic valve replacement in pre- and post-transcatheter aortic valve replacement eras at a structural heart center. *Front. Cardiovasc. Med.* 10:1103760. doi: 10.3389/fcvm.2023.1103760
- Lanzarone E, Vismara R, and Fiore GB (2009). A new pulsatile volumetric device with biomorphic valves for the in vitro study of the cardiovascular system. *Artificial Organs*, (12), 1048-1062. <https://doi.org/10.1111/j.1525-1594.2009.00812.x>



Thank you





Aortic Valve in **Formalin 4%**

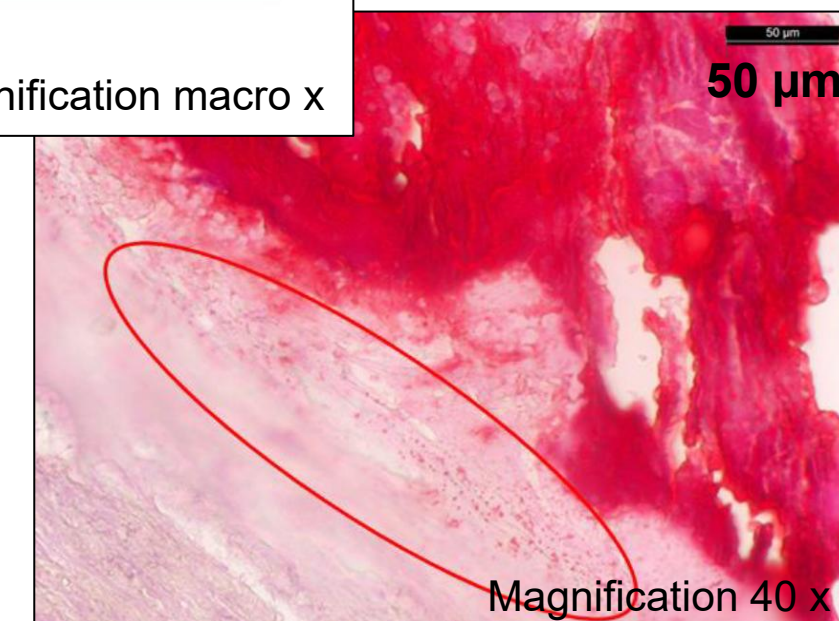
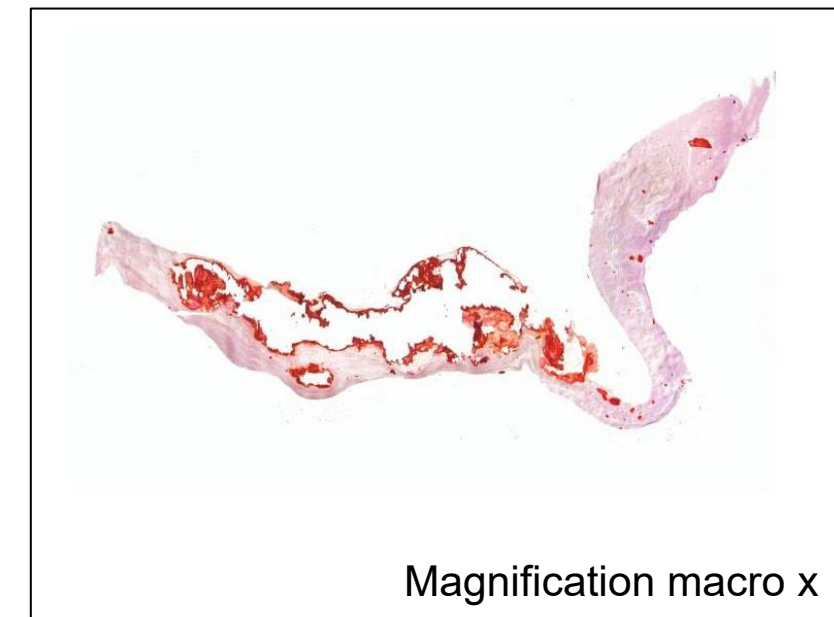
**Five samples** from each leaflet

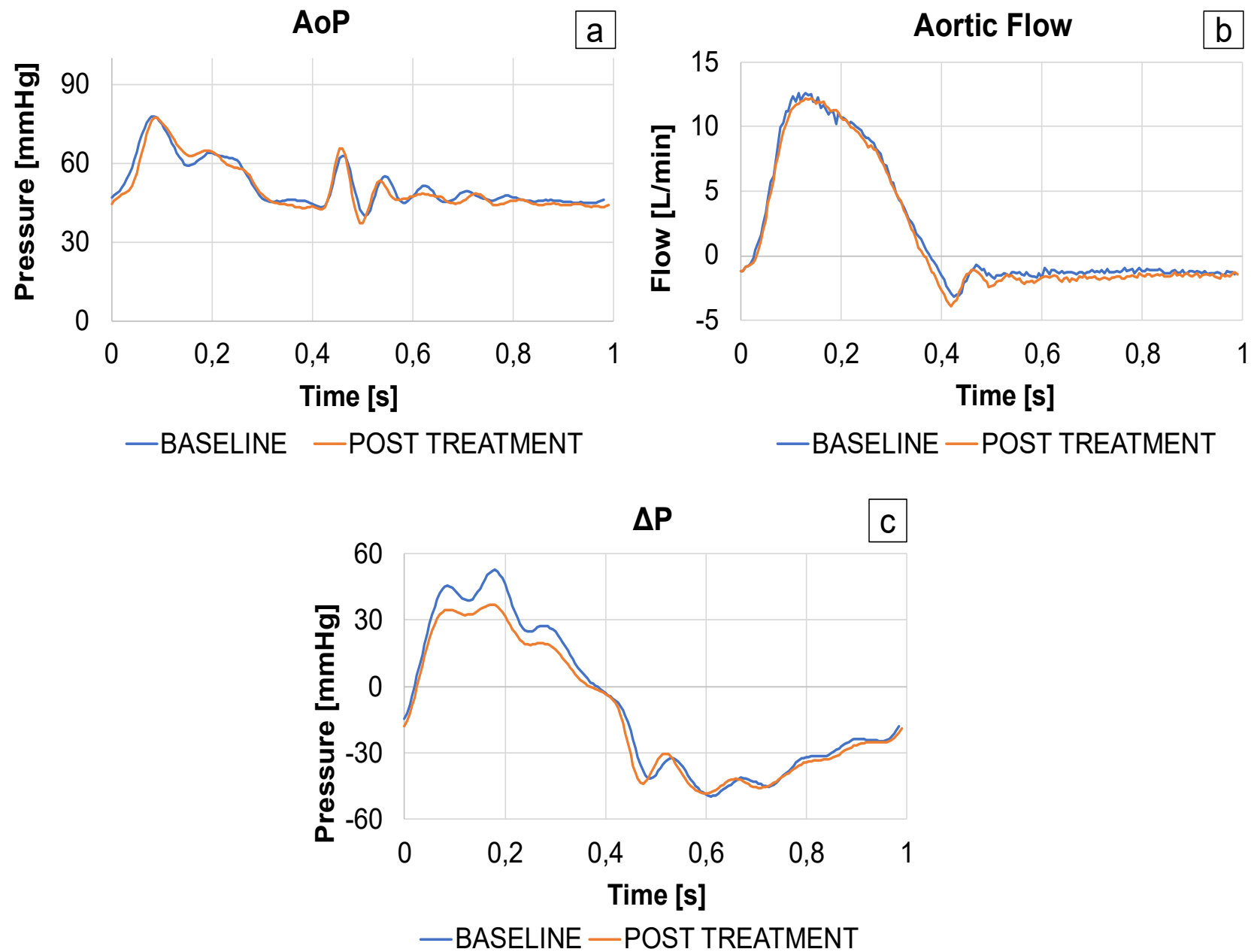
**Resin embedding** of the samples

Histological sections (4-5 $\mu$ m in thickness)

**Haematoxylin/Eosin** to highlight tissue components

**Alizarine Red S** to evidence the calcium deposition





	Sample1		Sample2		Sample3	
	baseline	post treatment	baseline	post treatment	baseline	post treatment
<b>Treated leaflets</b>	RCL		NCL and RCL		RCL	
<b>Conditions</b>						
AoP [mmHg]	50,15±0,05	50,08±0,03	51,83±0,33	50,90±0,22	51,77±0,41	50,82±0,07
SV [ml]	40,26±0,29	40,20±0,17	31,34±1,09	32,66±0,69	45,57±0,57	43,67±0,44
<b>Systole</b>						
ΔPsys [mmHg]	6,03±0,06	4,44±0,12	13,35±0,50	12,46±0,10	29,72±0,10	23,35±0,19
EOA [cm <sup>2</sup> ]	1,17±0,01	1,39±0,02	0,58±0,01	0,63±0,01	0,51±0,01	0,58±0,01
<b>Diastole</b>						
BV [ml]	9,23±1,06	18,25±1,28	15,75±0,90	19,37±1,29	14,31±1,81	18,84±1,33
ΔPsys variation [%]	-26%		-7%		-21%	
EOA variation [%]	18%		9%		14%	
BV variation [%]	98%		23%		32%	